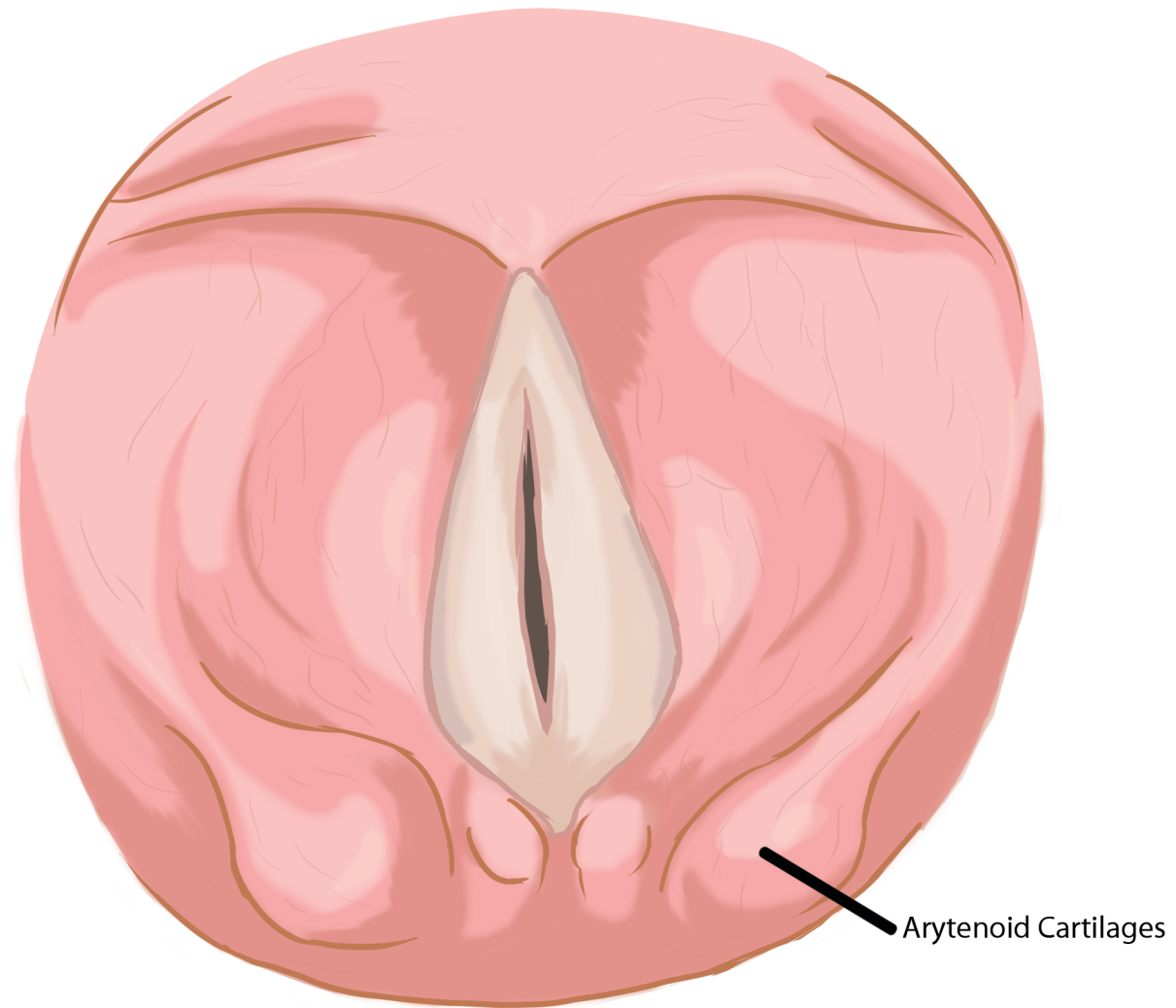


# The Vocal Folds in Falsetto

Front of Throat

Anterior

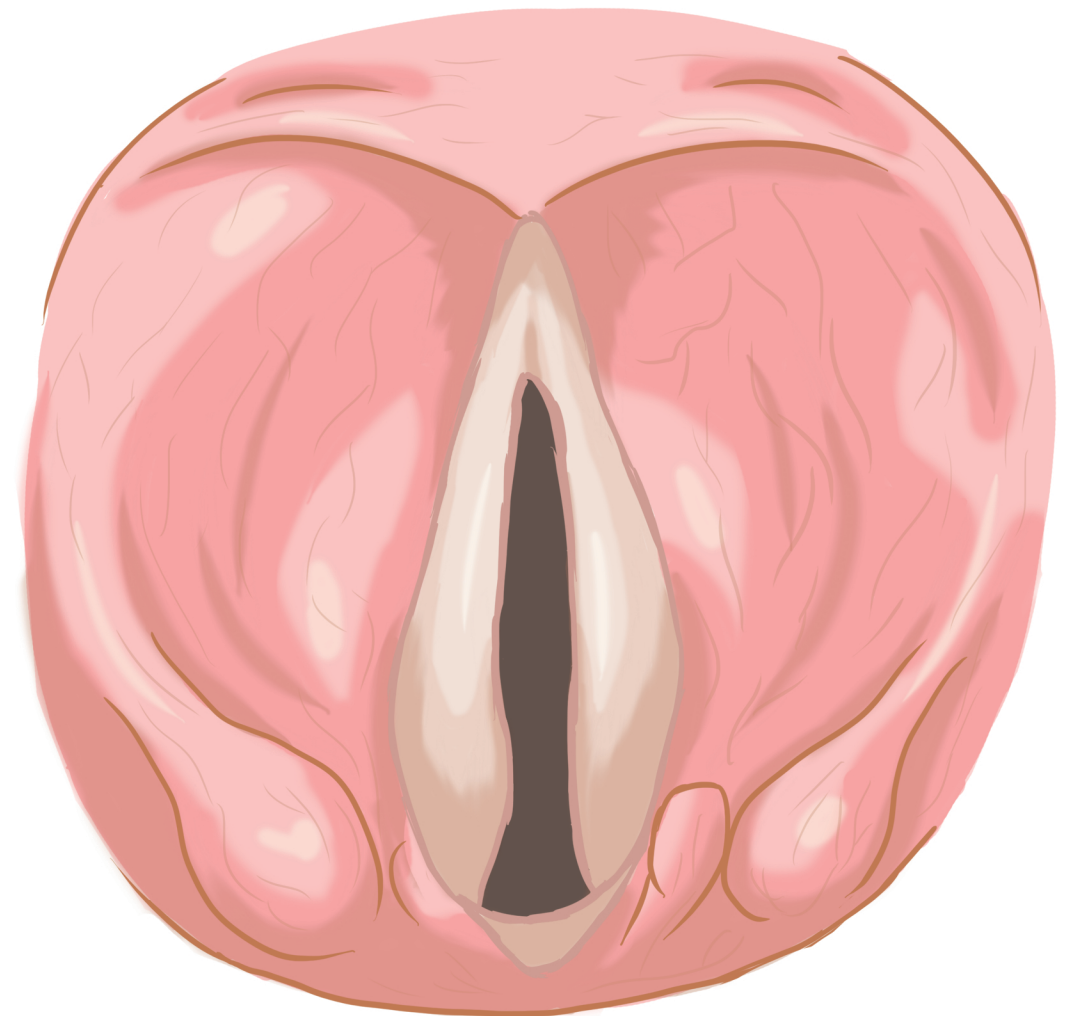

Arytenoid Cartilages

Posterior

Adducted or Vocal Cords together

Anterior



Falsetto - folds not at midline

Back of Neck