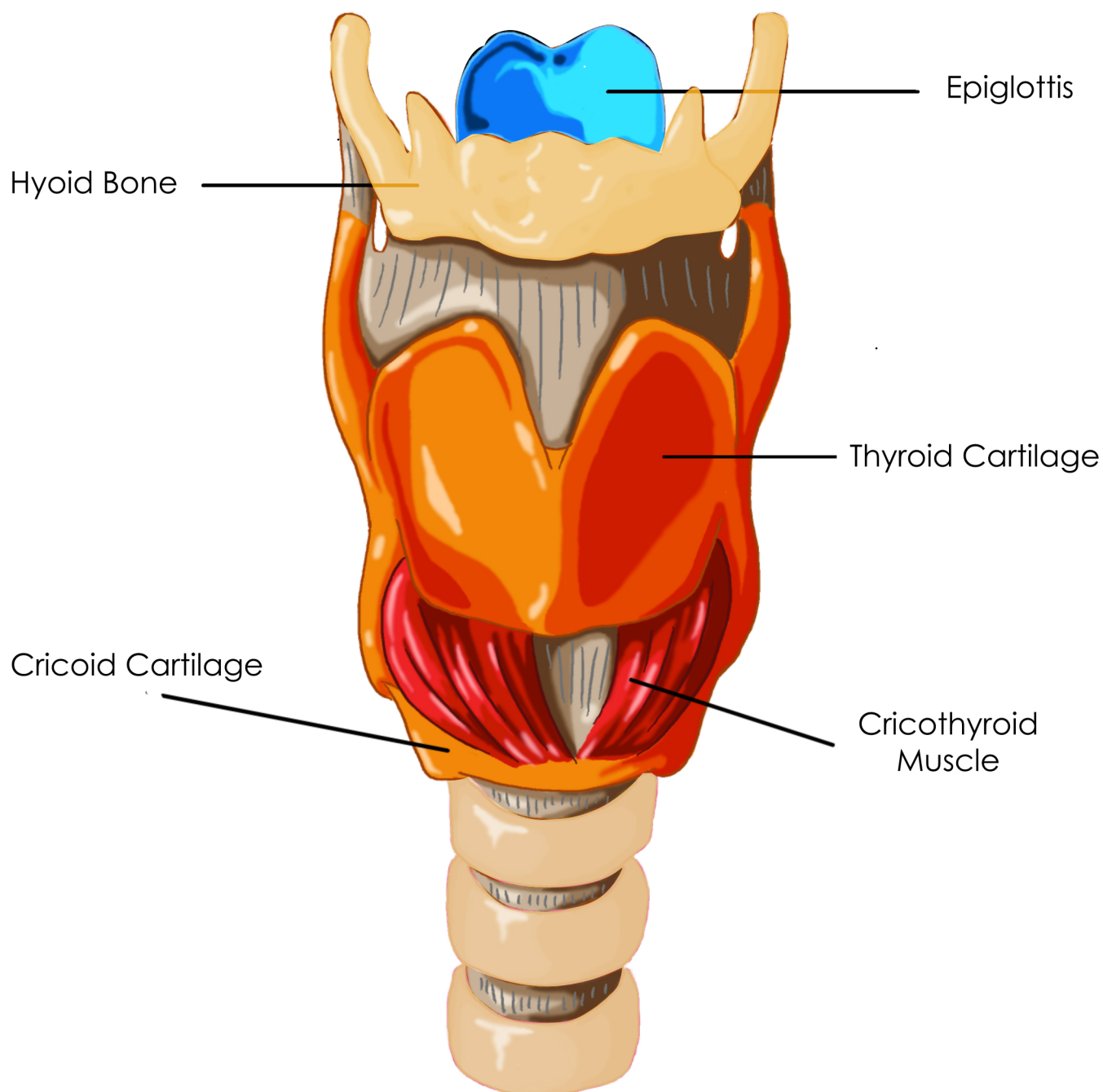


Cartilages of the Larynx- Epiglottis, Thyroid, Cricoid



The cricoid cartilage is the foundation of the larynx. It is shaped like a signet ring- thinner in front and thicker in back. The cricothyroid muscle draws the cricoid and thyroid cartilages together, stretching the vocal folds for higher pitches. The thyroid cartilage is also called the "Adams Apple"; it is the protective housing of the vocal folds. The epiglottis lifts when we inhale and closes over the trachea when we swallow, in order to protect the airway.

For more information about how your voice works please visit www.singlikeastar.com