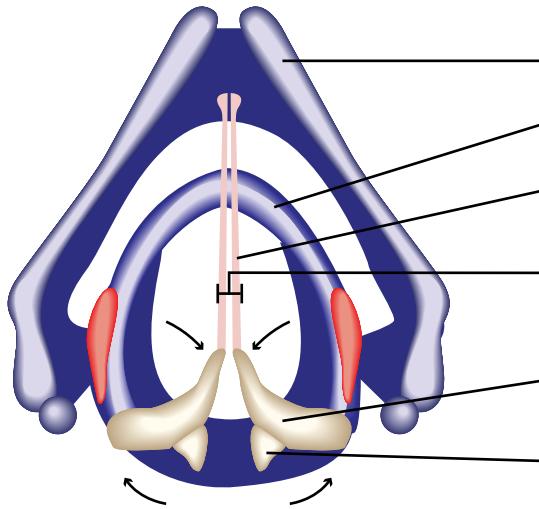


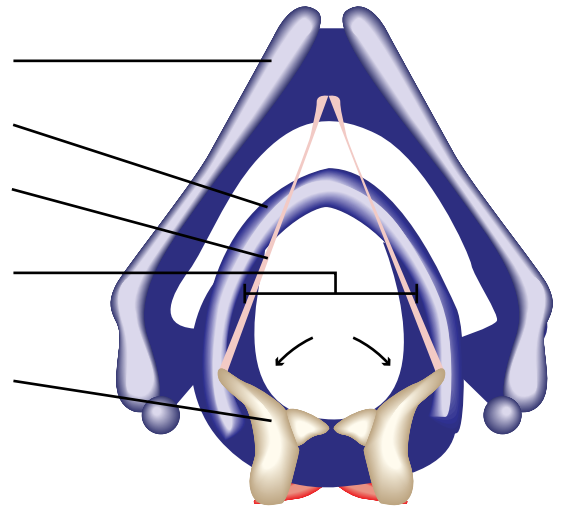
VOCAL FOLDS ADDUCTED AND ABDUCTED

Anterior



Closed glottis (**adducted**)

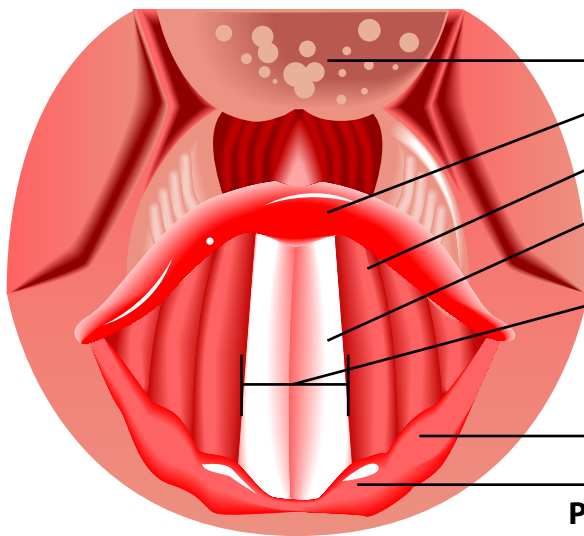
Thyroid Cartilage
 Cricoid Cartilage
 Vocal ligaments
 of true vocal cords
 Glottis
 (includes the space)
 Arytenoid cartilage
 Corniculate cartilage



Open glottis (**abducted**)

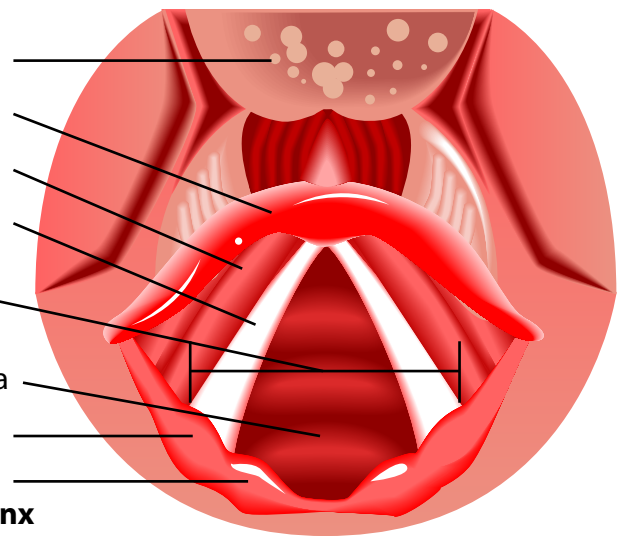
Posterior

Anterior: front of larynx



Vocal folds in closed position; closed glottis.

Base of Tongue
 Epiglottis
 Vestibular fold
 Vocal fold
 (true vocal cords)
 Glottis
 (includes the space)
 Inner lining of trachea
 Cuneiform cartilage
 Corniculate cartilage



Vocal folds in open position; open glottis.

Posterior: back of larynx

The vocal folds **adduct** or close to initiate phonation for singing or speaking. They **abduct** or open for inhalation and exhalation (respiration).

For more information about how your voice works please visit www.singlikeastar.com

